

**USE OF POINT OF CARE
ULTRASOUND (POCUS) IN THE
DIAGNOSIS OF A COMPLICATED
LOWER LIMB ABSCESS**

Ms Caitriona McGarrell (ANP(c), St James Hospital)

**Dr. Nicolas Yao-Han Lim (Specialist Registrar,
Emergency Medicine)**

November 2017

OVERVIEW

- Introduction
- Case study
- Clinical Practice Development
- Areas for future research



INTRODUCTION

- Skin and Soft tissue infections (SSTI) are common presenting complaints to the Emergency Department (ED).
- ED visits for SSTIs have doubled since the emergence of community acquired methicillin-resistant *Staphylococcus aureus* (MRSA) in the early 1990s.
- Abscesses can be difficult to diagnose due to the presence of oedema and indurated overlying skin.
- Since abscesses require incision and drainage, and cellulitis is treated with systemic antibiotics, distinguishing the two is essential.

(Berger *et al* 2011)



INTRODUCTION

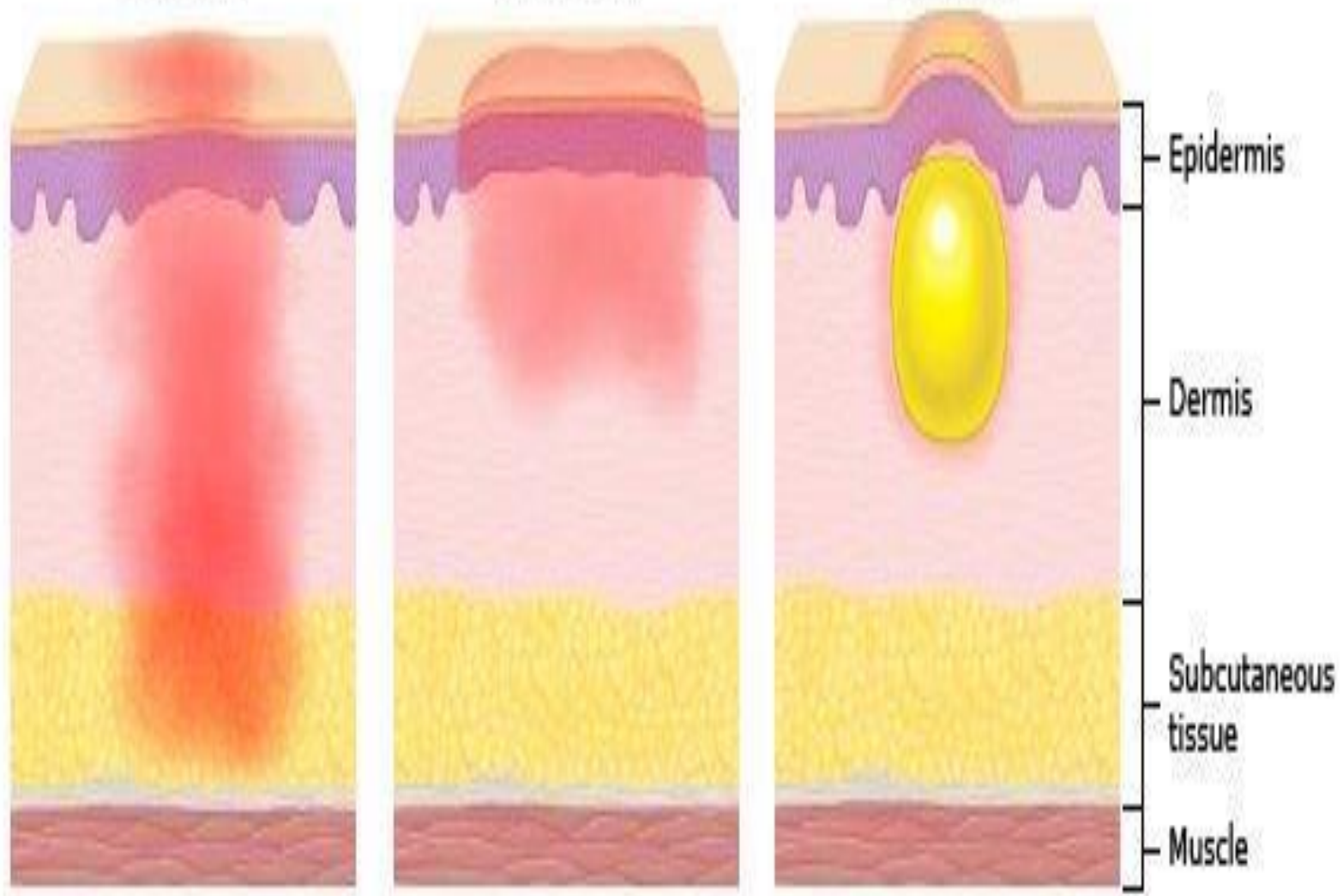
- POCUS: a rapid, non-invasive, painless, easily repeatable test, can distinguish between abscess and cellulitis in the vast majority of cases (Barbic *et al.* 2017).
- Ultrasound novices can positively discern the need for incision and drainage (Berger *et al.* 2011)

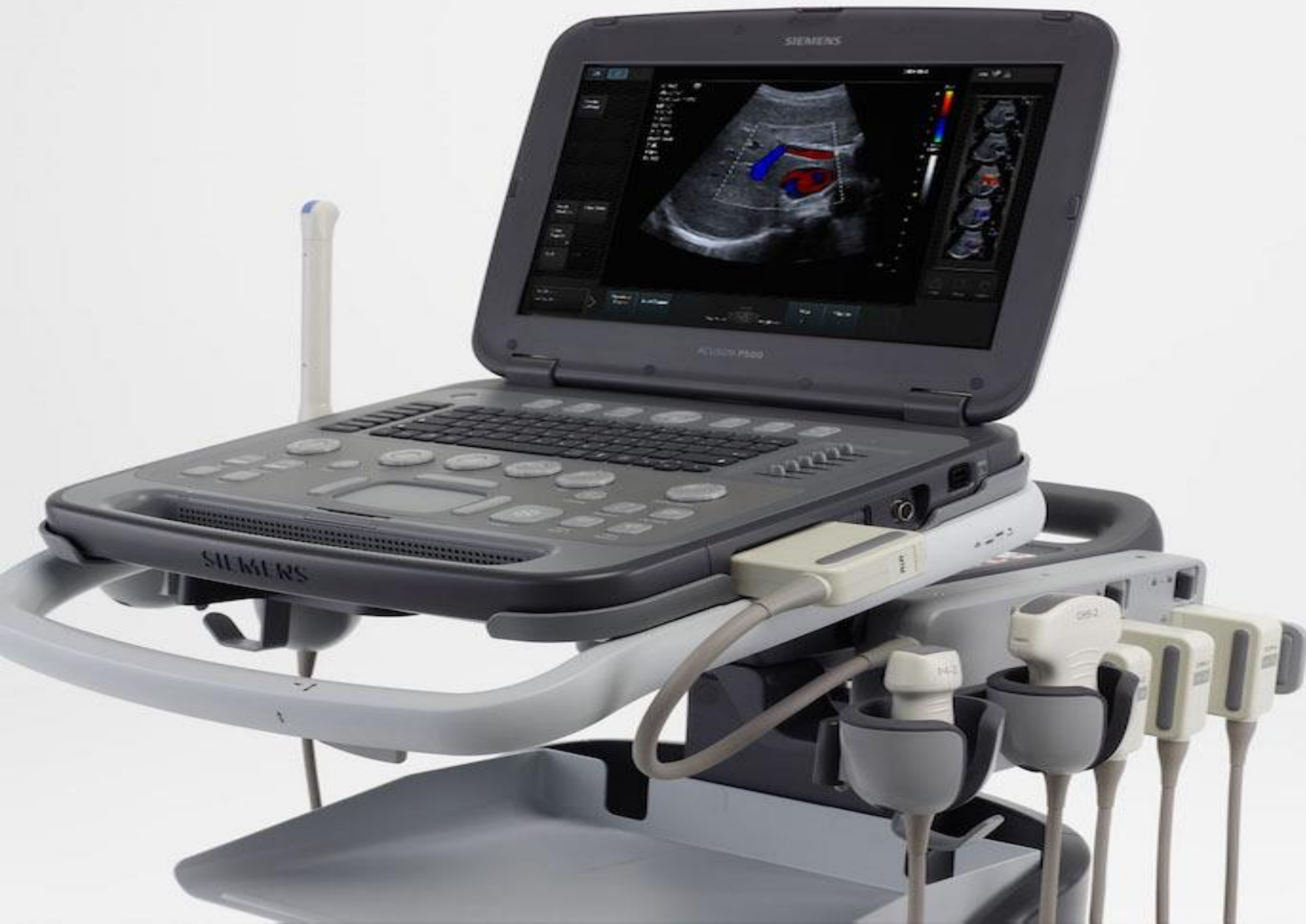

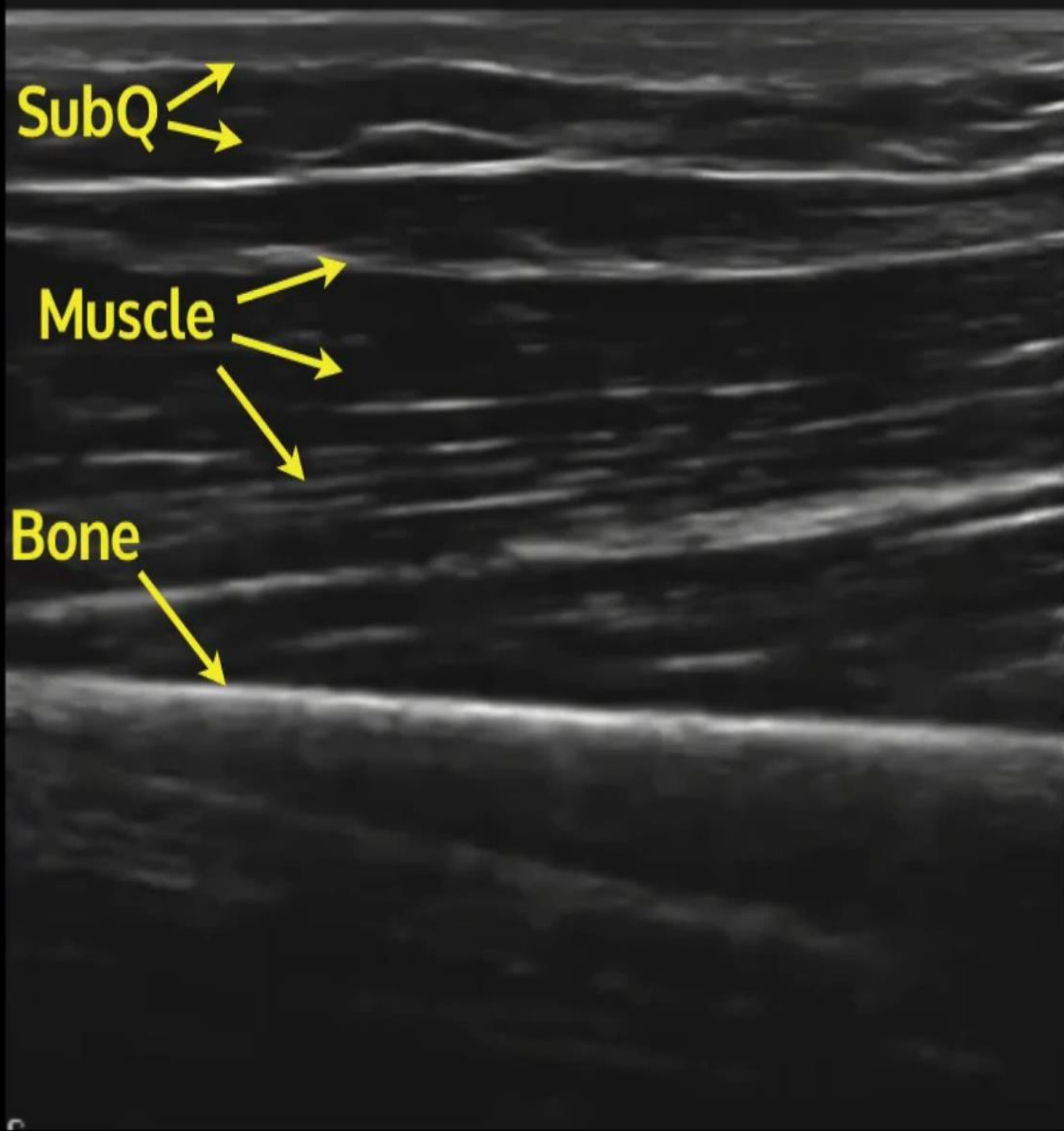
Cellulitis

Erysipelas

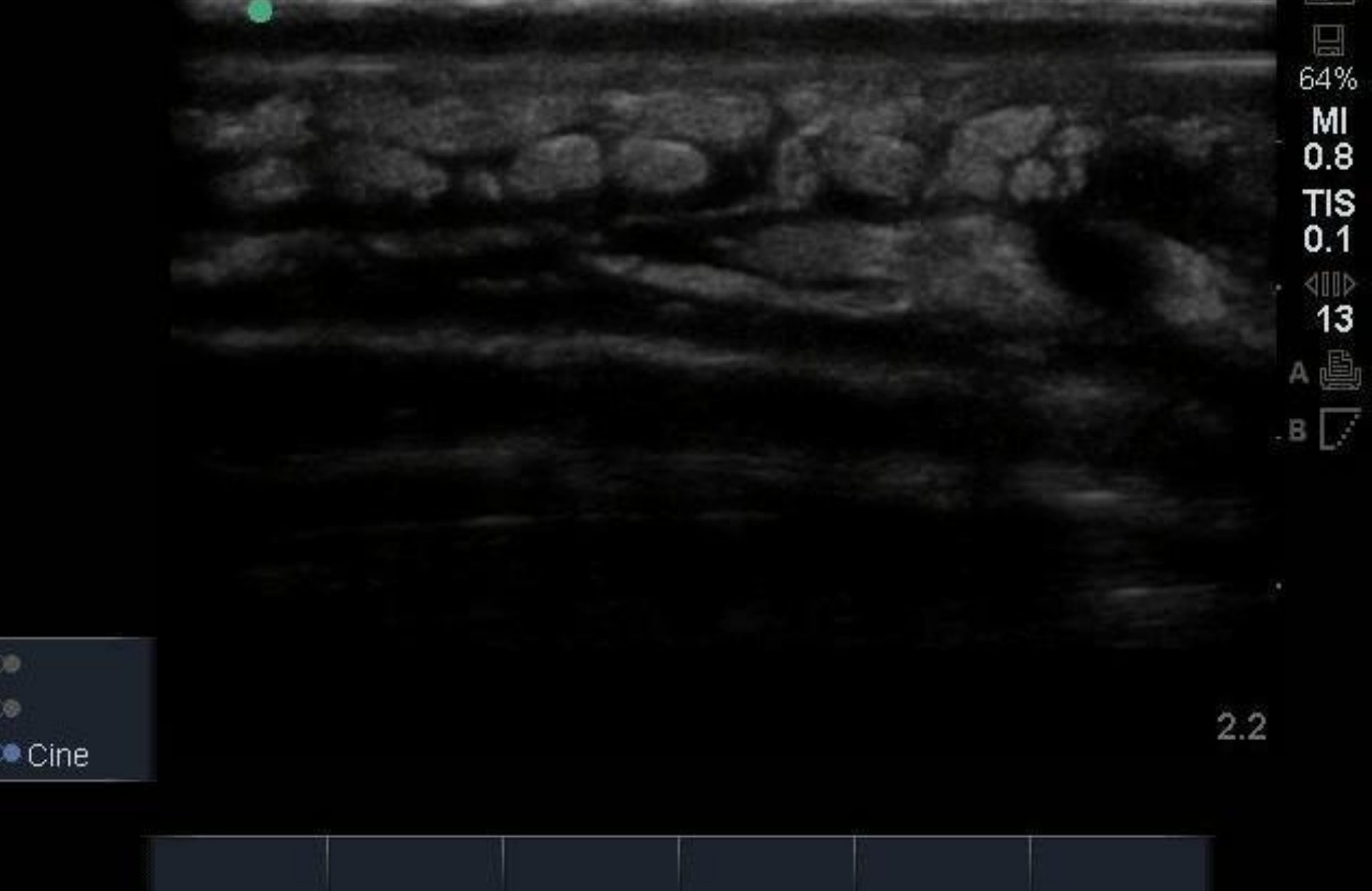
Abscess





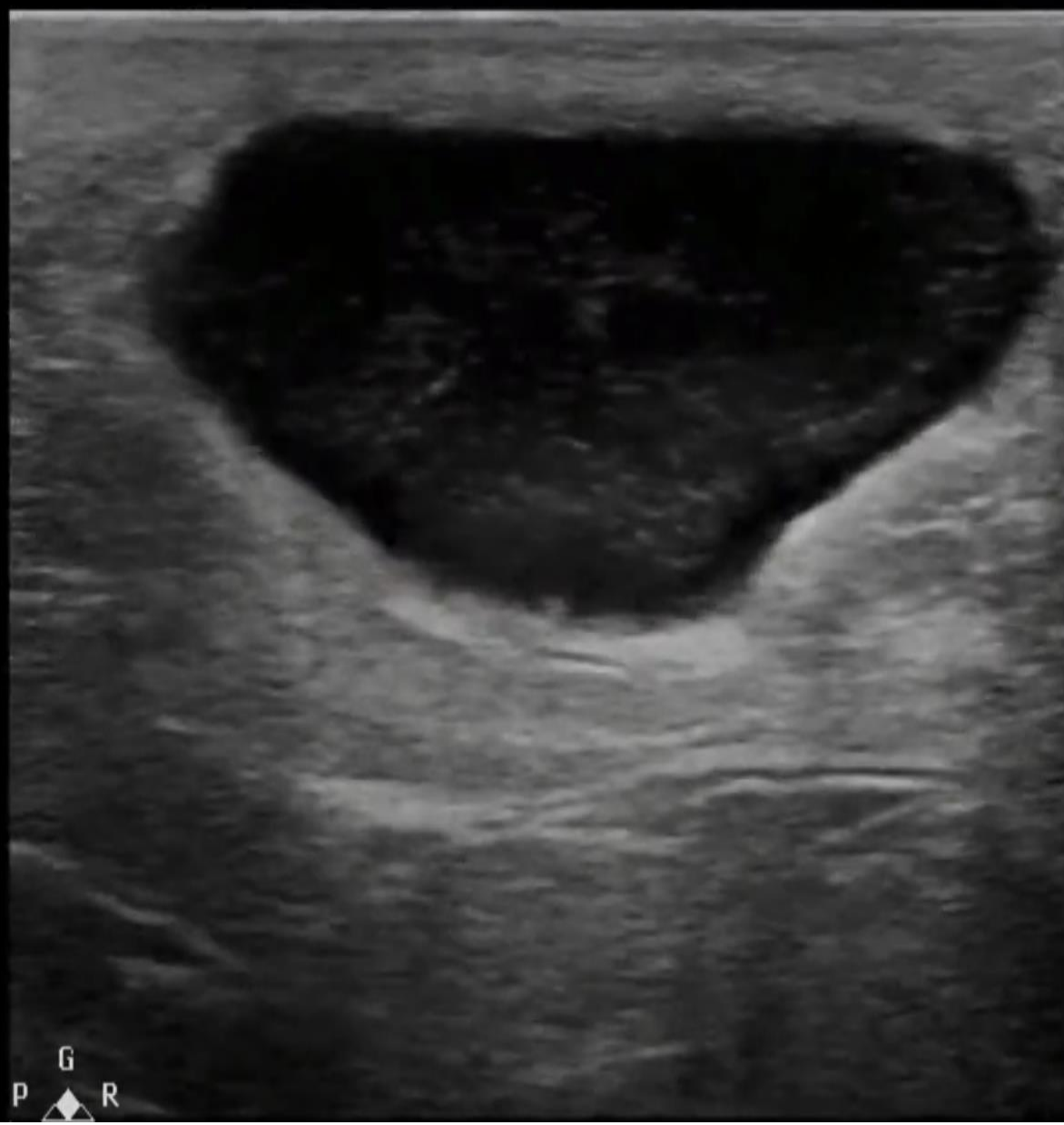

(Avila 2017)



(Avila 2017)

P



(Avila 2017)

CASE STUDY

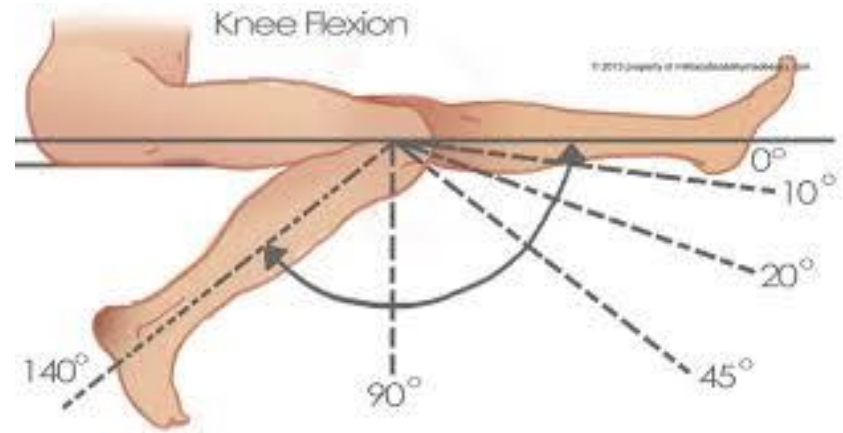
- Patient X
- 25 year old male
- Left knee pain x 10/7 post insect bites
- Med hx: Denies
- Meds: Augmentin, Ibuprofen
- Allergies: Arcoxia
- Occupation: Student
- Lives with parents



CASE STUDY

○ Assessment

- Systemically well.
- Partially weight bearing.
- The lateral aspect of his left knee from mid-thigh to mid-calf was swollen, indurated and erythematous.
- Knee flexion was to 45 degrees with full extension.



CASE STUDY

○ Impression

- ?Cellulitis
- ?Osteomyelitis

○ Plan

- X-Ray Knee to o/r Osteomyelitis
- Contact Infectious Diseases Team
- ED Medical Profile including Malaria screen and ESR
- Refer to Medical team for treatment of cellulitis.



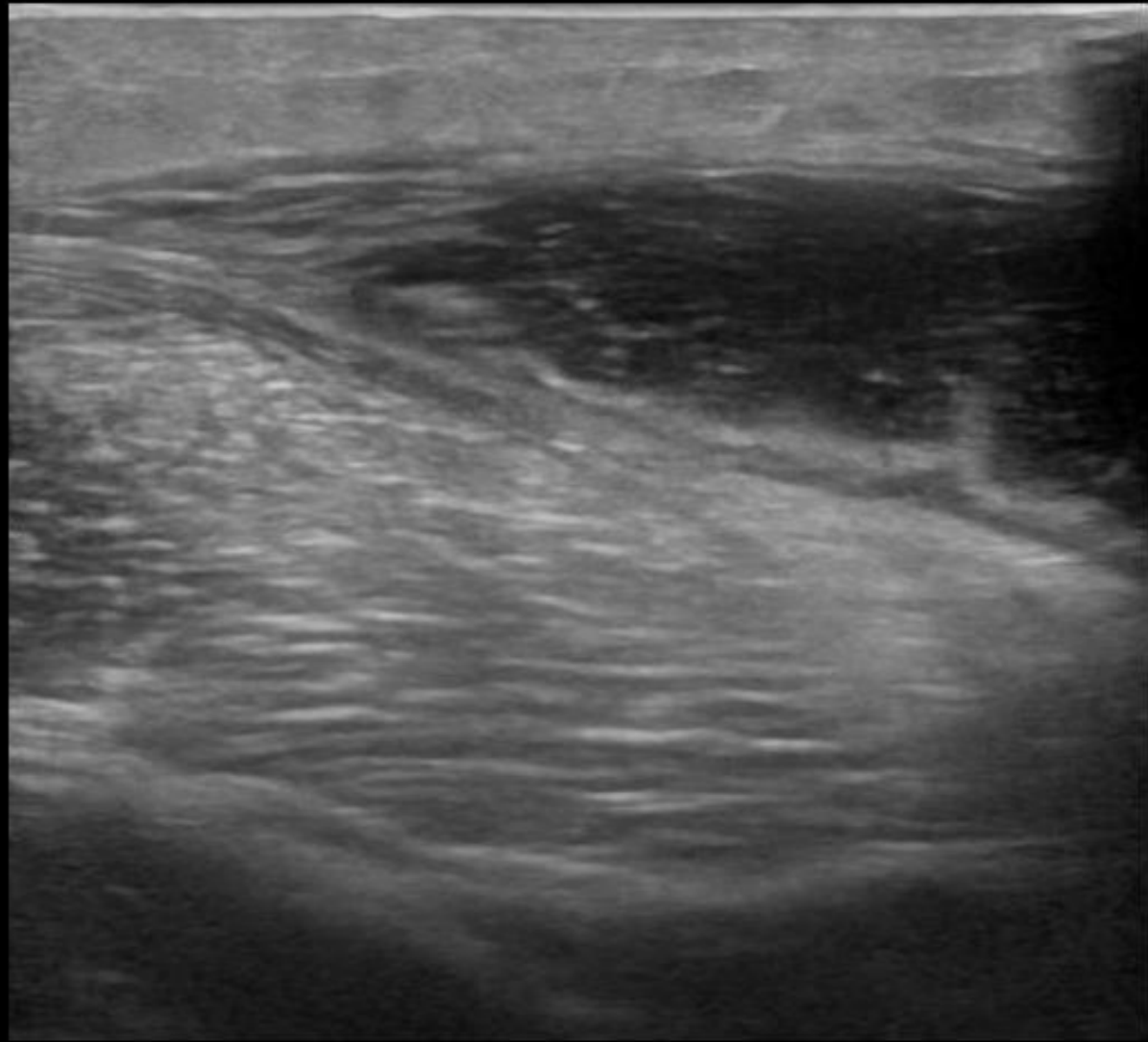
CASE STUDY

- Same day ultrasound not available.
- POCUS performed by the ED registrar showed sonographic signs of abscess deep to the iliotibial band.

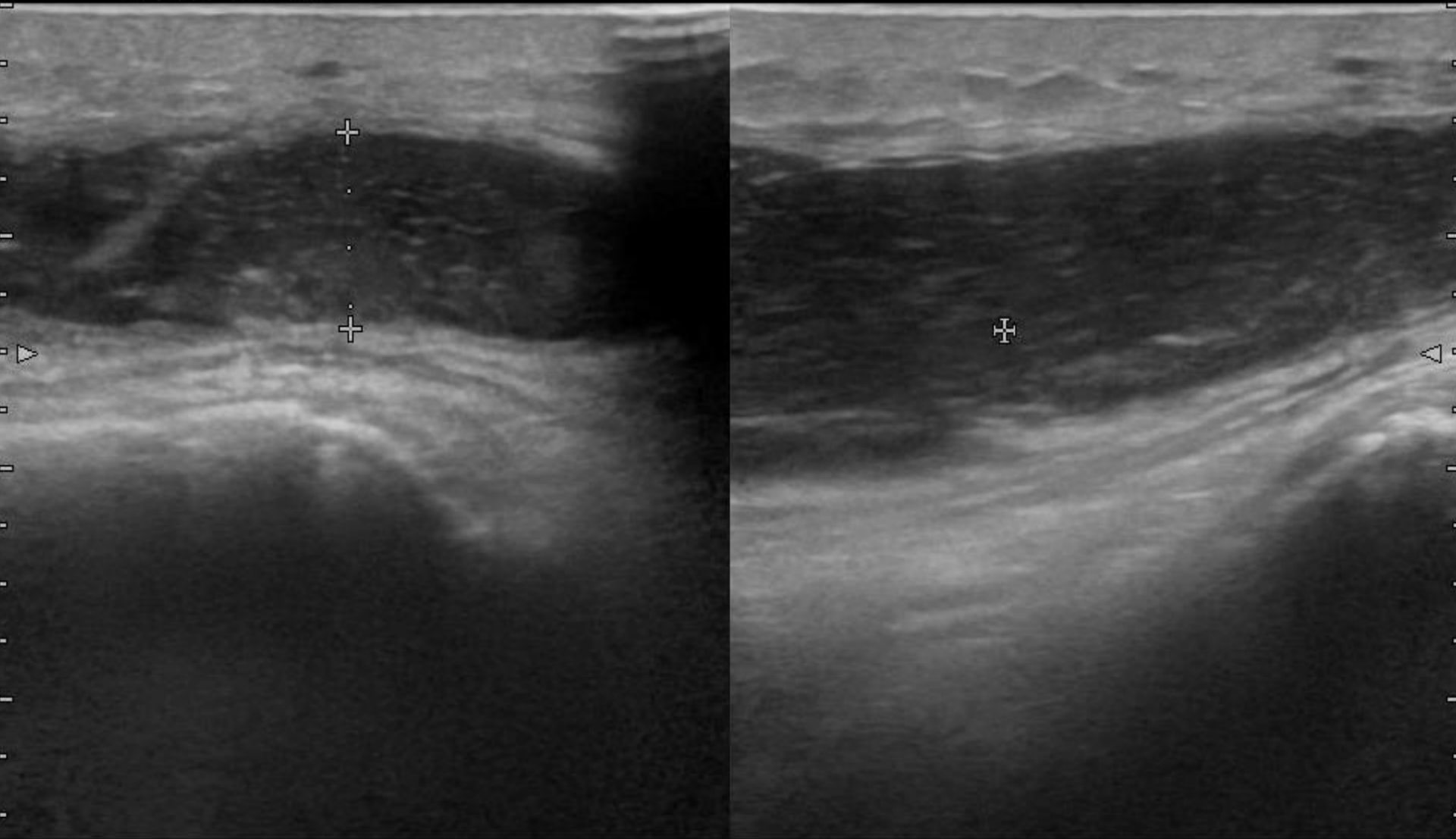




LT LAT KNEE



H
LT LAT KNEE



ip

w Menu

x

8.5 mm

CASE STUDY

- Patient referred to orthopaedic team for incision and drainage.
- Departmental ultrasound with aspiration completed.
- Pus sample positive for *Staphylococcus Aureus*
- Required 2 further washouts in theatre and was discharged on oral flucloxacillin for 14 days



CONCLUSION

- The use of POCUS for a more timely and accurate diagnosis has been shown in this case study to improve patient care by enabling referral to the appropriate speciality for definitive treatment.



CLINICAL PRACTICE DEVELOPMENT

- POCUS formal teaching session delivered by ED Registrar to ANP's.
- Assists in diagnosis of Skin and Soft tissue infections, fractures and tendon injuries.
- Additional diagnostic adjunct.



AREAS FOR FUTURE RESEARCH

- Audit of use of POCUS by ANPs
- Formal research into the effect of POCUS on diagnosis and management of SSTIs in the ED by ANPs.




REFERENCES

- Avila J. (2017) <http://5minsono.com/softtissue/>
- Barbic D., Chenkin J., Cho D., Jelic T., Scheuermeyer F. (2017) In patients presenting to the emergency department with skin and soft tissue infections what is the diagnostic accuracy of point-of-care ultrasonography for the diagnosis of abscess compared to the current standard of care? A systematic review and meta-analysis. British Medical Journal Open. doi:10.1136/bmjopen-2016-013688
- Berger T., Garrido F., Green J., Chun Lema P., Gupta J. (2012) Beside Ultrasound performed by novices for the detection of abscess in ED patients with soft tissue infections. The American Journal of Emergency Medicine. **30**,1569-1573



THANK YOU



??

